

Pregnancy as a ticking bomb: A sonographic review of type II cesarean section scar pregnancy*

BY MARIE THERESE ZAYCO-MAGNO, MD, FPOGS AND REGINA ROSARIO PANLILIO, MD, FPOGS, FPSUOG

Department of Obstetrics and Gynecology, Philippine General Hospital, University of the Philippines-Manila

ABSTRACT

Cesarean section scar pregnancy (CSP) is a pregnancy implanted outside the uterine cavity in the site of a previous cesarean section scar and is considered the rarest form ectopic pregnancy. CSP is a modern phenomenon and has been reported with increasing incidence due to either an increased reporting or increasing cesarean section rate. The true incidence, however, has not been fully determined as some cases will end up in the first trimester and go unreported or undiagnosed. Undiagnosed cesarean scar pregnancy can be fatal due to life threatening hemorrhage as well as uterine rupture due to an abnormally adherent placenta. Accurate diagnosis is important because it enables the clinicians to establish the risk of complications and aid in prompt management. Ultrasonography is often the first step in detecting CSP and MRI should only be used in equivocal cases. The case presented is in a multiparous woman with ultrasound finding of a cesarean scar pregnancy where expectant management was the initial option but because of the outward progression of the CSP, it was terminated. There is no established universal treatment guidelines for CSP and treatment options include expectant, medical, surgical or combinations of these.

Keywords: Cesarean scar pregnancy, Type II Cesarean Scar Pregnancy, Exogenic Type cesarean scar pregnancy,

INTRODUCTION

Cesarean section scar pregnancy (CSP) is defined as an ectopic pregnancy implanted outside the uterine cavity in the site of a previous cesarean section scar.^{2,4} The pathophysiology remains unclear but the most accepted theory seems to be that the blastocyst implants and invades into the myometrium through a microscopic dehiscence tract or niche, which may result from trauma of a previous cesarean section.^{2,5} The risk factors for a cesarean scar implantation is a history of cesarean delivery, number of prior cesarean sections, hysterotomy, dilatation and curettage, myomectomy, abnormal placentation, manual removal of placenta, short time interval between cesarean delivery and current pregnancy, single layer myometrial closure technique and retroversion of the uterus.^{1,7}

Ultrasonography is often the first step in detecting CSP and the use of Magnetic Resonance Imaging (MRI) should best be limited to equivocal cases.¹⁰ In the presence of a positive pregnancy test, a CSP can be diagnosed by adhering to certain set of sonographic criteria.

Until now, no universal treatment guidelines have been established.¹² Options include termination of pregnancy or continuation of pregnancy with the

possibility of delivering a live offspring, provided the patient understands that a morbidly adherent placenta may occur, often necessitating emergency hysterectomy.¹¹ To date, management for this condition includes expectant management, medical management, surgical management or mostly a combination of these.^{7,11}

CASE REPORT

This is a case of R.P., 32-years-old, female, from Tondo Manila who was admitted for an enlarging cesarean section pregnancy. She had bronchial asthma since childhood and no other illnesses reported. Her family medical history is non-contributory. She is a college undergraduate and is an occasional cigarette smoker but denies illicit drug use. Coitarche was at 16-years-old with 2 non-promiscuous sexual partner. She denies any history of sexually transmitted infection and use of contraception.

Menarche was at 12-years-old with regular monthly interval, 3 days duration and consumes 4 sanitary pads per day. She has no dysmenorrhea or any other premenstrual symptoms. She had 6 pregnancies in total with 5 live births, all delivered full term with no maternal and fetal complications. The first 4 pregnancies were delivered vaginally with the last 1 born via cesarean section, type unknown, for large baby 1 year prior to admission (2016).

This is her sixth pregnancy with her last normal menstruation on July 22, 2017 giving an age of gestation of 11 weeks and 3 days.

* Second Place, Philippine Society of Ultrasound in Obstetrics and Gynecology. (PSUOG) Interesting Case Contest, October 12, 2018, Satellite Office, Dr. Jose Fabella Memorial Hospital - Philippine Blood Disease and Transfusion Center, Quezon Avenue, Quezon City

Around 7 weeks prior to admission, the patient had missed her menses prompting her to obtain a pregnancy test which revealed a positive result, giving her an approximate age of gestation of 4-5 weeks. Prenatal check-up was done where ultrasound was requested and revealed no sonographic evidence of pregnancy at that time.

Six weeks prior to admission, at around 5-6 weeks age of gestation, repeat transvaginal ultrasound showed a cesarean scar pregnancy. She was advised to seek consult to a tertiary hospital but was unable to do so.

Eighteen days prior to admission, at 8 weeks and 6 days age of gestation, the patient had vaginal spotting which prompted her to seek consult at the outpatient department of a tertiary hospital. She was immediately sent to OB admitting section where work-up was initiated. A transvaginal ultrasound was done showing the uterus to be midline with a well circumscribed complex mass at the anterior lower uterine segment, at the level of the cesarean section scar which measured 4.6 x 4.8 x 4.9 cm (Figure 1). Within the mass was a gestational sac measuring 2.7 x 2.8 x 2.5 cm with mean sac diameter of 2.7 cm. The crown rump length measured 2.1 cm equivalent to 8 weeks and 5 days age of gestation with fetal heart rate of 179 bpm. The yolk sac measured 0.4 cm. The mass occupied the full myometrial thickness of the anterior lower uterine segment but the uterine serosa and posterior bladder wall were intact and distinct from each other (Figure 2). Color flow mapping and power Doppler of the complex mass showed abundant vascularity around the mass more prominent at the inferior area probably at the placental implantation site (Figure 3). The cervix measured 2.9 x 3.9 x 3.2 cm with intact endocervical canal and no mass within (Figure 4). The anterior and posterior endometrium is hyperechoic measuring 0.7 cm anteriorly and posteriorly with low level echo fluid interface in between. The right ovary was normal, while the left ovary was not visualized. There were neither adnexal masses nor pelvic fluid noted.

The patient was admitted with an admitting diagnosis of cesarean section pregnancy, 8 weeks and 6 days age of gestation by amenorrhea, unruptured, S/P cesarean section type unknown for fetal macrosomia (2016), G6P5 (5005). Further ancillary tests were done which revealed a normal result.

Management options were thoroughly discussed with the patient and her family. At this time, the patient decided for expectant management hoping for the possibility of continuing pregnancy. The patient was then discharged on the third hospital day with the instruction to follow up with repeat ultrasound after 2 weeks or any time she becomes symptomatic. Furthermore, she was constantly checked out by the resident in-charge making certain that her condition remains stable.

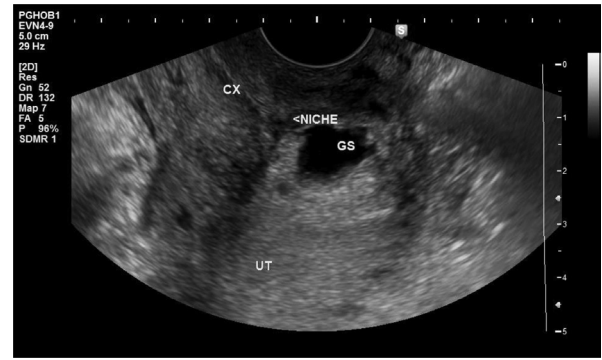


Figure 1. A magnified transvaginal sagittal ultrasound scan showing the cervix (CX) with an empty endocervical canal. The gestational sac (GS) is located above the internal cervical os at the anterior lower uterine segment and within the cesarean section niche

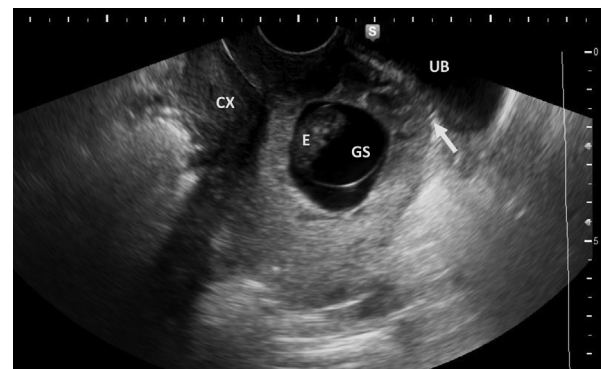


Figure 2. A transvaginal sagittal view showing the CSP to occupy the full myometrial thickness of the anterior lower uterine segment but do not protrude out to the urinary bladder. The uterine serosa and posterior urinary bladder wall is thin but distinct (arrow); Cervix (CX), Embryo (E), Gestational Sac (GS), Urinary Bladder (UB)

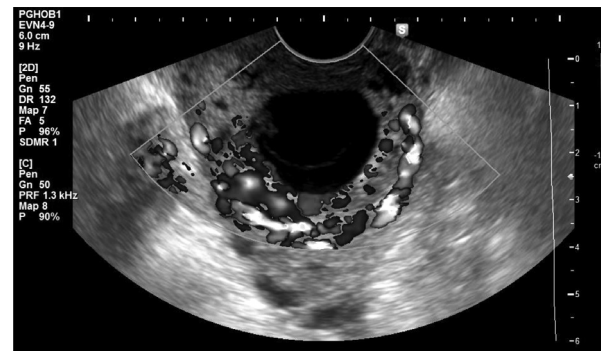


Figure 3. Color flow mapping of the CSP showed abundant vascularity surrounding the mass more prominent at the inferior portion.

Fifteen days after discharge, the patient had her follow up check-up. At this time she is 11 weeks and 3 days age of gestation by amenorrhea and she remained asymptomatic. Repeat ultrasound was done revealing the previously seen well circumscribed complex mass now measures 9.9 x 8.6 x 7.6 cm, seen at the left anterior lower

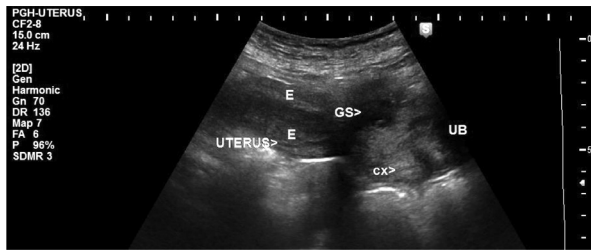


Figure 4. Transabdominal panoramic view of the uterus showing its relationship with the urinary bladder (UB); The endometrium (E) with empty endometrial cavity; The gestational sac (GS) is positioned at the anterior lower uterine segment; The cervix (CX) is empty

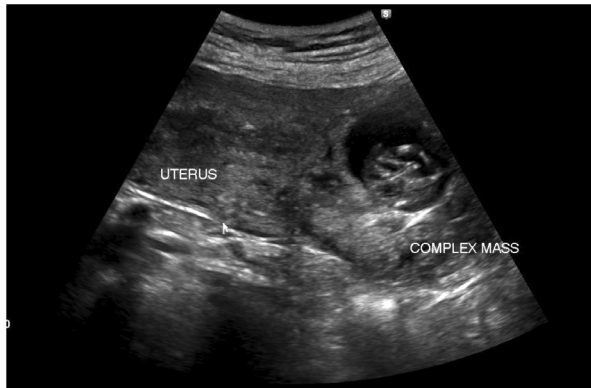

Figure 5. Transabdominal sagittal ultrasound scan showing the previously seen complex mass is enlarging and seen at the left anterior lower uterine segment.

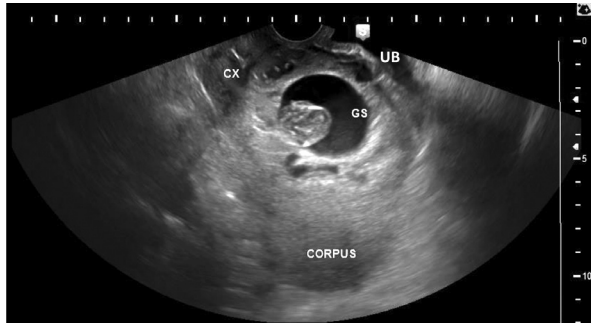


Figure 6. Transabdominal sagittal ultrasound scan showing expansion of the lower uterine segment bulging out to the posterior urinary bladder wall (UB) and the upper third of the cervix (CX); GS (Gestational Sac)

uterine segment (Figure 5). The mass occupied the full thickness of the anterior lower uterine segment extending to the left upper third of the cervix, bulging out to the posterior urinary bladder wall (Figure 6). The uterine serosa and the posterior urinary bladder wall remained intact and distinct (Figure 7). The mean sac diameter measured 4.6 cm. The crown rump length measured 4.6 cm equivalent to 11 weeks and 3 days age of gestation with a fetal heart tone of 171 beats per minute. The yolk sac measured 0.4 cm. Color flow mapping and power Doppler of the complex mass showed abundant vascular

flow more prominent at the inferior portion (Figure 8). There was no free fluid in the pelvic cavity.

Due to an enlarging cesarean scar pregnancy, the patient was admitted with an admitting diagnosis of cesarean section pregnancy, 11 weeks and 3 days age of gestation by amenorrhea, cesarean section pregnancy, unruptured, S/P cesarean section type unknown for fetal macrosomia (2016), G6P5 (5005). The situation was discussed again with patient and her family including the risk of uterine rupture and other catastrophic effects of the said condition. With informed choice, the patient and her family decided to continue with expectant management, hence discharge was contemplated.

On the fourth hospital day, at 12 weeks age of gestation, the patient developed mild hypogastric pain and vaginal bleeding. This time, the patient and the family opted to terminate the pregnancy and decided to undergo hysterectomy since she had completed family size. The surgery was very well planned and she was referred to necessary specialties. Enough blood products and medications were secured.

On the sixth hospital day, at 12 weeks and 2 days age of gestation, the patient underwent exploratory laparotomy, bilateral internal iliac artery ligation, total hysterectomy and bilateral salpingectomy under epidural anesthesia. Intraoperatively, no ascites was noted and both fallopian tubes and ovaries were grossly normal. The uterus was enlarged and deviated to the right and measured 13.5 x 8.0 x 5.0 cm with smooth serosal surface. The anterior lower uterine segment was thinned out (Figures 9 and 10). On cut section, seen within the lower uterine cavity was a gestational sac measuring 6.5 x 6.0 x 4.0 cm with a single fetus with a crown-rump length of 7.0 cm. The endometrium was decidualized measuring 0.3 cm (Figure 11). The cervix was smooth deviated to the right and measures 3.5 x 3.0 x 3.0 cm (Figure 12). Postoperative diagnosis was cesarean section pregnancy 12 weeks and 2 days age of gestation by amenorrhea, S/P cesarean section, type unknown, for fetal macrosomia (2016), G6P5 (5015).

The surgery went well with an estimated blood loss of 1100 cc. One unit of packed red blood cell was transfused intraoperatively and patient tolerated the procedure well.

On the following days post-surgery, recovery was satisfactory. The bowel and urinary function returned accordingly. There were no febrile episodes and post-operative laboratory results were also normal. The patient was discharged improved on the fourth day post-surgery.

The patient had followed up at the outpatient department 1 week after discharge. She has no subjective complaints and the surgical wound was well coaptated. Surgical Pathological report revealed a gestational endometrium, chronic cervicitis and normal fallopian tubes (Figure 13).

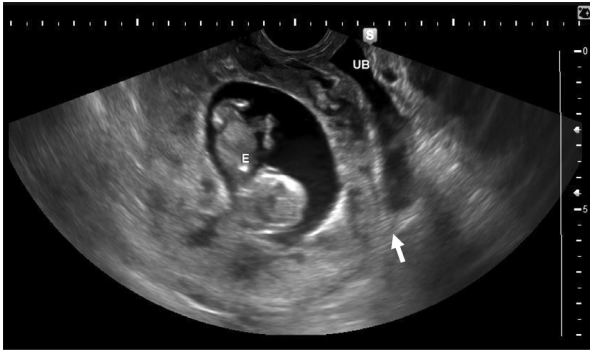


Figure 7. Transvaginal sagittal scan showing the cesarean section pregnancy to occupy the full thickness of the anterior lower uterine myometrium but the uterine serosa and the posterior urinary bladder wall (UB) to be distinct (arrow); E (Embryo/ Fetus)

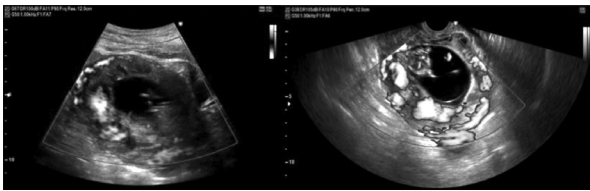


Figure 8. Color flow mapping (left) and power Doppler (right) of the cesarean section pregnancy showed abundant vascular flow around the mass

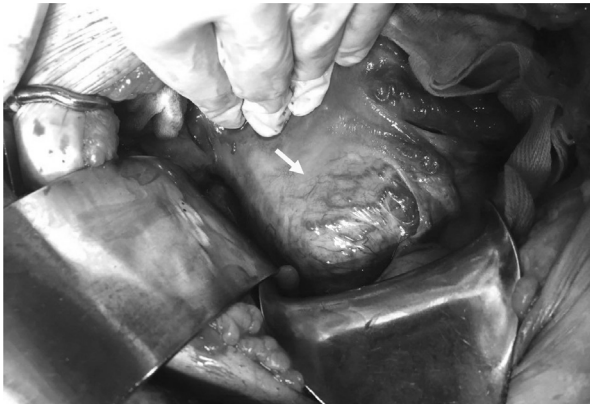

Figure 9. Intraoperatively, the anterior lower uterine segment was thinned out but with smooth serosal surface; Increased blood vessels are also noted in this area. (arrow)

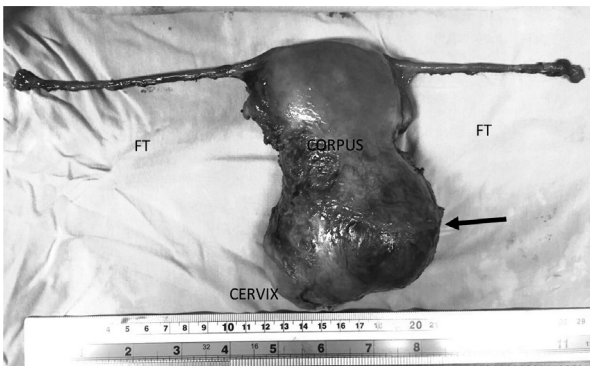


Figure 10. Shows the uterus to be enlarged with smooth surface with the cervix deviated to the right. the anterior lower uterine mass (arrow) is seen bulging out anteriorly and to the left. Both fallopian tubes (FT) are grossly normal.

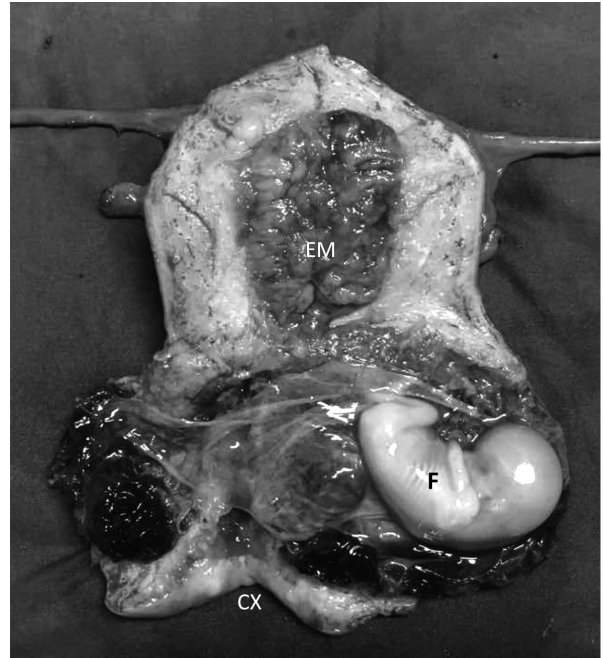

Figure 11. On cut section of the uterus is an empty endometrial cavity with decidualized endometrium (EM). A gestational sac with fetus (F) is seen occupying the anterior lower uterine segment pushing down to the proximal half of the cervix (CX)

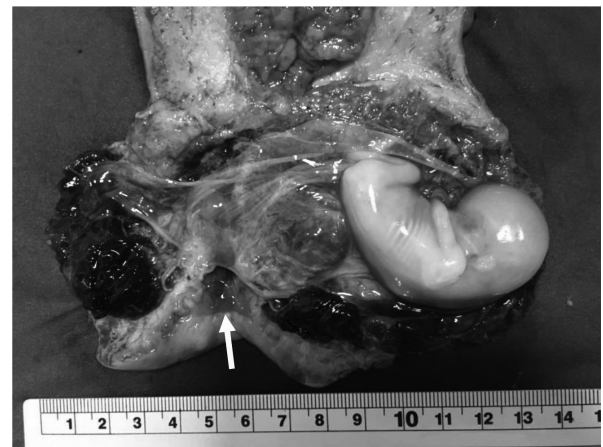


Figure 12. Showing a magnified view of the cut section of the cervix wherein the cervical canal is intact (arrow). The cesarean section pregnancy is positioned more to the left and pushing down the proximal half of the cervix

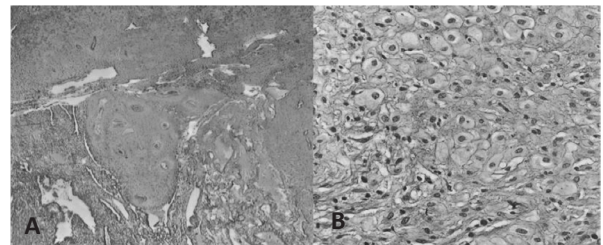


Figure 13. Histopathological report (A): Endomyometrial Interface at 40 x magnification (B) Gestational endometrium at 400 x magnification

CASE DISCUSSION

Ectopic pregnancy is the implantation of blastocyst outside the endometrium of the uterine cavity and occurs in 1.9% of reported pregnancies.¹ Most of ectopic gestations are located in the fallopian tubes, however, ectopic pregnancies are also known to occur in the cervix, ovary, abdomen and previous cesarean scar.³ Cesarean section scar pregnancy (CSP) is defined as an ectopic pregnancy implanted outside the uterine cavity in the site of a previous cesarean section scar with myometrium and fibrous scar tissue surrounding it completely.^{2,4} Intramural pregnancy with implantation in a previous cesarean section scar is probably the rarest location for an ectopic pregnancy.²

Cesarean scar pregnancy is a modern phenomenon. The increase incidence is thought to be either due to increased reporting or increasing global cesarean section rate.⁵ The true incidence of CSP has not been fully determined but is estimated to range from 1:1800 to 1:2216 and constitutes 6.1% of all ectopic pregnancies in women with history of cesarean deliveries.¹ The true prevalence of CSP is likely to be somewhat higher than estimated in literature as some cases will end up in the first trimester, either as miscarriage or termination, and go unreported or undiagnosed.⁵ An article from a local journal in 2016 reported that there was one reported case in Philippine General Hospital who have delivered a term neonate but the pregnancy was complicated by placenta accreta hence underwent cesarean hysterectomy. Likewise, there were 2 cases reported in 2014.¹⁶

The pathophysiology of CSP remains unclear.⁵ The most accepted theory seems to be that the blastocyst implants and invades into the myometrium through a microscopic dehiscence tract or niche, which may result from trauma of a previous cesarean section.² The very presence of scar tissue may have an additional more global impact on the endometrium which allows aberrant implantation.⁵ Occurrence of intramural implantation of a blastocyst can also be seen in any other gynecologic surgery, manual removal of placenta and in vitro fertilization and embryo transfer.²

According to Saba et al, the only the risk factor for a cesarean scar implantation is a history of cesarean delivery.⁶ The number of prior cesarean sections, hysterotomy, dilatation and curettage, myomectomy, abnormal placentation, manual removal of placenta, short time interval between cesarean delivery and current pregnancy, single layer myometrial closure technique and retroversion of the uterus may lead to cesarean section scar dehiscence, increasing the chance of implantation of the blastocyst in this region.^{1,7} Approximately 72% of CSP occur in women who have had more than two cesarean deliveries.⁹

The index patient has had only 1 cesarean delivery done 1 year prior and that is her only clear cut risk factor for developing CSP. However, the surgical technique of the previous cesarean section was unknown since the operative technique could not be retrieved from the institution where it was done. Additionally, the circumstances of her vagina birth were also unknown.

Any woman with prior cesarean delivery should be aware of the possibility of CSP.³ On review of various case reports, it was noted that CSP were incidental sonographic finding in an asymptomatic woman while some present with mild painless vaginal bleeding. In a lesser percentage of patients, it was accompanied with mild to moderate abdominal pain. The uterus maybe tender during examination if CSP is in the process of rupture. A patient with ruptured CSP may present in a state of collapse or hemodynamically unstable.⁸

The discovery of CSP in the index patient was actually just an incidental finding on a first trimester scan since she only had a positive pregnancy test and was asymptomatic. Vaginal spotting and mild hypogastric pain occurred later at around 12 weeks age of gestation.

In a review of more than seven hundred cases of CSP, Timor-Tritsch et al found that diagnosis was missed in more than 13% of cases. Making the correct diagnosis is important because it enables the clinicians to establish the risk of complications associated with CSP and can aid in prompt management.⁷ Ultrasonography is often the first step in detecting CSP.¹⁰ Sonography combined with Doppler flow imaging has been advocated as a reliable tool for detecting these cases.² Ultrasound is highly useful for diagnosing CSP in the early stages of pregnancy, with a sensitivity of 86.4% and specificity of 92%.¹⁰ One study showed that contrast enhanced MRI resulted in the accurate diagnosis of CSP in 95.5% of cases, as opposed to ultrasound. However, the use of MRI should best be limited to equivocal cases on ultrasound, due to prolonged acquisition time.¹⁰

Transabdominal ultrasound maybe used to obtain a panoramic view of the uterus, prior to a closer inspection with the transvaginal probe. The CSP usually presents as a heterogeneous mass, containing cystic-solid, or mixed echoes within the cesarean scar.¹⁰ In the presence of a positive pregnancy test, a CSP is diagnosed by ultrasound using the following criteria:¹

- Visualization of empty uterine cavity as well as an empty endocervical canal
- Detection of the placenta and/or gestational sac embedded in the hysterotomy scar
- In early gestations (< 8 weeks), a triangular gestational sac that fills the niche of the scar and at more than 8 weeks, this shape becomes rounded or even oval
- A thin (1-3 mm) or absent myometrial layer between

the gestational sac and the urinary bladder

- A closed and empty cervical canal
- The presence of embryonic or fetal pole and or yolk sac with or without heart activity
- The presence of a prominent and at times rich vascular pattern at or in the area of a CSP

The ultrasound done for the index patient accomplished all of the sonographic criteria for the diagnosis of CSP. For 1 the cervix is closed and the cervical canal is distinct and empty. Second, the complex mass was well circumscribed, with gestational sac, yolk sac and a live embryo seen at the anterior lower uterine segment, above the internal os, at the level of the previous cesarean scar. These are enough findings to rule out cervical pregnancy. Third, the uterine cavity is empty. The complex mass occupied the full thickness of the myometrium leaving only an intact uterine serosa. Color flow mapping showed abundant vascular flow around the complex mass. Diagnosis of a CSP at that time was certain.

Adherence to these set of diagnostic criteria may help reduce the risk of misdiagnosis and potentially catastrophic consequences of this condition.¹⁰ There are several conditions that should be considered as differential diagnoses for CSP. Differentiating a CSP from a cervical ectopic pregnancy depends upon the identification of the internal os. A CSP implants in the lower uterine segment above the internal os, whereas a cervical pregnancy implants into the wall of the cervix below the level of the internal os.⁹

In cases of spontaneous miscarriage in process where one would expect to see the gestational sac in the cervico-isthmic space, color Doppler may be utilized to differentiate this condition from CSP.^{7,10} During an uncomplicated miscarriage, the gestational sac may overlie the scar, however, color Doppler examination can confirm implantation within the uterine cavity. Trophoblastic implantation posterior to the gestational sac and away from the scar is evident. Alternatively, a lack of peri-trophoblastic flow, in the case of inevitable miscarriage would indicate a diagnosis of the cervical phase of miscarriage although embryonic cardiac activity may still be present.⁷ Spontaneous miscarriage will give be positive the "sliding organ sign" whereby displacement of the sac in the cervico-isthmic space can be observed with gentle probe pressure.¹⁰

In a review done by Comstock on the antenatal diagnosis of placenta accreta, they have found out that patients with placenta accreta on pathologic examination presented with a low lying gestational sac majority of which were clearly attached to the uterine scar. The myometrium was thin in the area of the scar to which the scar was attached. This type of pregnancy is differentiated

from CSP to which the pregnancy is entirely contained within the myometrial confines of the scar.¹⁵

Although rare, CSP can also sonographically mimic gestational trophoblastic neoplasia especially those located in the cervico-isthmic area. There was a case reported in 2013 by Sobi et al where a cervicoisthmic choriocarcinoma mimics a cesarean scar pregnancy.¹⁴

In cases where CSP is suspected or equivocal, and the patient is hemodynamically stable, interval ultrasound or MRI maybe useful in making the diagnosis.¹⁰

Viel et al had classified CSP into 2 different types, and most authors believe that the difference is of paramount importance.^{1,2} The first type of CSP, also known as type I or endogenic type, implants over the scar but proceeds to develop within the uterine cavity. It may appear as a viable intrauterine pregnancy, complete with yolk sac, embryo and cardiac activity. This type of CSP may progress to viable gestational age with possible problems with placentation.⁵ Type II or the exogenic type, are pregnancies that implants more deeply within the scar and grow in the direction of the serosal surface of the uterus towards the broad ligament or urinary bladder. A thin layer of myometrium, usually less than 5 mm, can be seen at early gestations between the gestational sac and the serosa and as pregnancy grows this layer disappears. Consequently, the pregnancy bulges through the scar defect with much greater rate of early uterine rupture and subsequent hemorrhage.⁵

Ultrasound is useful in differentiating both types of CSP. In type I CSP, the deformity seen on ultrasound is less apparent as the implantation grows towards the uterus. Hence, the ultrasound image can appear as a viable pregnancy. High index of suspicion cannot be over emphasized as differentiating type I CSP from a normal pregnancy can often only be made by ultrasound at earlier gestation.⁵

The initial ultrasound of the index patient done in this institution is positive for a CSP. However, at that time it was not certain whether it will progress as a type I or type II CSP. On the second scan, it was clearer that the gestation progressed as type II CSP as evidenced by the mass growing outward towards the urinary bladder and pushing to the left upper third of the cervix. This phenomenon have brought the patient and the attending physicians in a situation where everything was uncertain. The situation was complicated because the pregnancy was as fragile as a ticking time bomb, ready to explode anytime.

Once the occurrence of CSP is established and the type defined, the patient should be counselled about her options. Literatures from the past decade makes evidence based counselling possible. The presence of a live CSP requires immediate and decisive action to prevent further growth of the embryo or fetus.¹¹

In general, treatment should be individualized based on the patient's age, number of previous cesarean deliveries, number of children, need for future child bearing, hemodynamic condition, the viability of pregnancy, severity of myometrial defect, beta hCG level and the site, size and vascularity of the pregnancy.^{1,7,11} The expertise of clinicians managing the patient and the available infrastructure are also factors.^{1,11} Options include termination of pregnancy or continuation of pregnancy with the possibility of delivering a live offspring, provided the patient understands that a morbidly adherent placenta may occur, often necessitating emergency hysterectomy.¹¹

Despite the prominent increase, no universal treatment guidelines have been established until now, and the management of CSP in daily clinical practice is still based on anecdotal reports and small series.¹²

The main goal of treatment for CSP is to prevent massive blood loss and to conserve the uterus to maintain future fertility, women's health, and quality of life.⁹ Therefore termination of pregnancy in the first trimester is generally recommended.¹² Type II CSP presents a greater treatment challenge than type I CSP.¹³ To date, management options for this condition includes expectant management, medical management, surgical management or mostly a combination of these.^{7,11} Gynecologic surgeons generally perform dilatation and curettage, laparoscopy, hysteroscopy or laparotomy. Obstetricians, and in vitro fertilization specialists usually prefer systemic administration of methotrexate or ultrasound guided local methotrexate or potassium chloride injection to the gestational sac. On occasion, the help of an interventional radiologist maybe requested to embolize the area of CSP through the uterine artery.¹¹

In case of CSP type I, successful births have been described with expectant management, but the prognosis of an uneventful term pregnancy is poor. The hysterectomy rates are considerably high because of the increased risk of morbidly adherent placenta, uterine rupture and related life threatening massive hemorrhage.¹²

Initially, systemic methotrexate has been adopted as first line approach for CSP treatment. A systematic review done Pektas et al in 2016, showed that using systemic methotrexate was successful in only 8.7%. There was 62.1% complication rate mostly because it required second treatment, and hysterectomy rate of approximately 4%.^{11,12} The high failure rate maybe caused by its slow action and questionable ability to stop cardiac activity.¹² Also, multidose methotrexate regimen can have a cumulative adverse effects on the liver and bone marrow.¹¹ These findings point out the inappropriateness of recommending methotrexate as a first line approach for CSP.¹²

Ultrasound guided intra-gestational sac injection of methotrexate or potassium chloride had the fewest and

least-involved complication. Of the 83 cases reviewed by Timor-Tritsch et al in 2014, only 9 cases (10.8%) involved complication. Cases performed with transabdominal guidance had a slighter complication rate than those using transvaginal guidance. Because local injection provides a final treatment by stopping heart activity, they appear to be an effective intervention and maybe especially useful when future fertility is desired.¹¹

Utilization of uterine artery embolization (UAE) in association with systemic or local administration of methotrexate for the treatment of CSP was reported in several case series. UAE alone had a complication rate of 80%, and complimentary treatment was required in 82% cases.¹² UAE is not the best first line treatment because the delay between treatment and effect allows gestation to grow and vascularity to increase.¹¹ Thus, it's use should be limited to cases with significant bleeding or a high suspicion index of arteriovenous malformation.¹²

Dilatation and curettage as first line approach is discouraged since it can lead to profuse bleeding and complementary treatment procedures that may return blood transfusions and laparotomy. Literatures shows that dilatation and curettage alone had a complication rate of 63%.¹²

Hysteroscopy allows direct visualization of the gestational sac and coagulation of the related vascular texture at the implantation site so that any profuse bleeding maybe prevented. Although this procedure requires general anesthesia, trained health staff and operative equipment, it offers shorter duration of resolution, avoidance of toxicity, shorter postoperative hospital stay, lesser blood loss and rapid return to fertility.^{11,12} Timor-Trich et al in his review states that if hysteroscopy was combined with transabdominal ultrasound guidance, no complication was noted in 9 cases cases.¹¹ Another review by Pekata in 2016 showed it that hysteroscopy was successful in 39% and there was no need for hysterectomy.¹² An expert review designated hysteroscopy as an optimal first-line approach for CSP with lowest complication rate.¹²

Inserting a foley catheter and inflating it at the site of the CSP is an ingenious, relatively new approach. They can be used alone in gestations of 5-7 weeks in the hope of stopping the evolution of pregnancy by placing pressure on a small gestational sac. The catheter is inserted with either a transabdominal or transvaginal real-time sonographic guidance to allow for more precise placement, assess the pressure and avoiding over inflation. Timor-Tritsch and colleagues had a positive impression of this method.¹¹

In an article by Collins and Kothari they motioned the use of high intensity focused ultrasound (HIFU), where the ultrasound itself is the embryocidal agent. It is a non-invasive and non-surgical technique where the heat

energy it emitted is directed at the gestation, stopping cardiac activity and resulting in rapidly falling HCG. This technique was found to be effective for larger gestation with strong peripheral flow.¹⁰

Wedge excision of CSP by hysterotomy is mandatory when uterine rupture is confirmed or strongly suspected. This conventional surgery allows complete removal of the CSP and simultaneous repair of the myometrial scar.¹² Excision can either be through a laparotomy or laparoscopy.

In 2015, Yun-Yan et al compared management of CSP type II by medical management in the form of UAE combined with methotrexate versus surgical treatment in the form of surgical mass excision and scar repair by laparotomy. The study demonstrated that all CSP II patients treated with UAE combined with methotrexate required systemic methotrexate application with 4 of the 15 patients suffering from severe bleeding. Hence, findings suggest that UAE combined with methotrexate is not a good option for treatment of CSP II. Meanwhile, patients who underwent surgery did not suffer any complication. The surgery group success rate was 100% whereas the medical group success rate was 73%.¹³

With the advent of minimally invasive surgery and the lesser complications that accompanies it, the first CSP case successfully treated by laparoscopy was reported in 1999.¹³ Laparoscopic wedge resection is justified in hemodynamically stable women who have deeply implanted gestational sac growing toward the abdominal cavity and bladder. A systematic review in 2016 by Pektas demonstrated that hysterotomy successfully treated 92% of reviewed CSP cases and hysterectomy was required in only 2% of the cases.¹² Some researchers have suggested that laparoscopy maybe reasonable alternative to laparotomy for an unruptured CSP.¹³ Laparotomy is available in all hospitals, but in hospitals that offers laparoscopy, laparoscopic CSP resection with wound repair is a safe and effective treatment for CSP II, especially after and failure of medical management.¹³

The reason for performing hysterectomy in CSP is usually a lifesaving procedure in cases massive bleeding.¹⁰ But then, hysterectomy was also reported as a primary mode of treatment or when other treatment modalities failed.⁸

Evidence based counseling was done in the management of the index patient. She was given options where initially she decided to go for expectant management. However, when the fear of uterine rupture came in, she decided to terminate pregnancy by undergoing hysterectomy since she had already 5 offspring.

CONCLUSION

It was not so long ago when cesarean section pregnancy was considered rarest among the ectopic pregnancies. Presently, the incidence rose and the importance of correctly establishing the condition is very important. It was not so long ago either, when the role of ultrasound in this phenomenon is only in the diagnosis. Now, aside from diagnosis, ultrasound can be utilized in the management as well. It can be utilized in the diagnosis of the sequelae related of CSP, such as the development of arteriovenous malformations, persistent gestational sac and gestational trophoblastic disease, as well as postoperative complications such as hematoma formation. As such, sonologist should be more aware in detecting CSP in the first trimester in all women with history of cesarean section even when screening for CSP is still of unproven value.

In this situation, team work never failed when the sonologist acted as detective reporting the occurrence of an urgent danger, that is the cesarean pregnancy awaiting to explode and bring catastrophes. But then, the obstetrician prevented the explosion time, saving one precious life. ■

REFERENCES

1. Vora, PH, Bansal, V. Cesarean scar pregnancy: clinicians challenge. *Int J Reprod Contracept Obstet Gynecol.* 2017 May; 6(5):2101-2013.
2. Aich R, Solanki N, Kakadiya K, Bansal A, Jshi M, Nawale A. *Radiol Case Rep.* 2015 December; 10(4):68-71.
3. Xing X, Zhang X, Yan P, Gao C, Sun Q. *In J Clin Exp Med.* 2016; 9(9): 17267-17273.
4. Jagtap V, Samant P, Valvi D, Parulekar SV. Cesarean scar ectopic pregnancy: diagnostic and therapeutic dilemmas. *JPGO.* 2015; 2(4):1-4.
5. Paterson K, Odejinmi F, Shahid A. Clinical dilemmas and risks of misdiagnosis and mismanagement associated with endogeneous caesarean scar pregnancy: a case series and literature review. *Glob J Reprod Med.* 2017; 3(1):1-5.
6. Berhie SH, Molina RL, Davis MR, et al. Beware the scar: laparoscopic hysterectomy for 7-week cesarean delivery scar implantation pregnancy. *Am J Obstet Gynecol.* 2015; 212:247.e1-2.
7. Goodhart V, Jurkovic D. Ultrasound diagnosis of cesarean scar pregnancy. *RAD Magazine.* 42, 490, 21-22.
8. Roy MM, Radfar F. Management of viable cesarean scar pregnancy: a case report. *Oman Med J.* 2017; 31(2):161-166.
9. Norton M, Scout L, Feldstein V. Callen's ultrasonography in obstetrics and gynecology 6th edition. Philadelphia: Elsevier Inc: 2017. 990-991 p.
10. Collins K, Kothari A. Catastrophic consequences of a cesarean scar pregnancy missed on ultrasound. *Australas J Ultrasound Med.* 2015 Nov; 18(4):150-156.
11. Timot-Tritch, MD, Monteagudo A, Goldsterin S. How to identify and manage cesarean scar pregnancy. *OBG Management.* 2014 June; 26(6):19-28.
12. Pekta M, Bodur S, Dundar S, Akir V. Systematic review: what is the first-line approach for cesarean section pregnancy?. *Taiwanese Journal of Obstetrics & Gynecology.* 2015 March; 55(2016):263-269.
13. Sun YY, Xi X, Yan Q, Qiao Q, Feng Y, Zhu Y. Management of type II unruptured cesarean scar pregnancy: comparison of gestational mass excision and uterine artery embolization combined with methotrexate. *Taiwanese Journal of Obstetrics & Gynecology.* 2014 January, 54 (2015):489-492.
14. Sorbi F, Sisti G, Pieralli A, Tomasco M, Livi L, Buccoliero A. Cervicoisthmic choriocarcinoma mimicking cesarean section ectopic pregnancy. *J Res Med Sci.* 2013 October; 18(10):914-917.
15. Comstock C. Antenatal diagnosis of placenta accreta. *Ultrasound Obstetric Gynecol.* 2015; 26: 89-96
16. Elep R, Dalawangbayan M. Evolution of cesarean scar pregnancy into a placenta accreta at term: A case report. *PJOG.* 2017 July-August; 41(4):29-36.